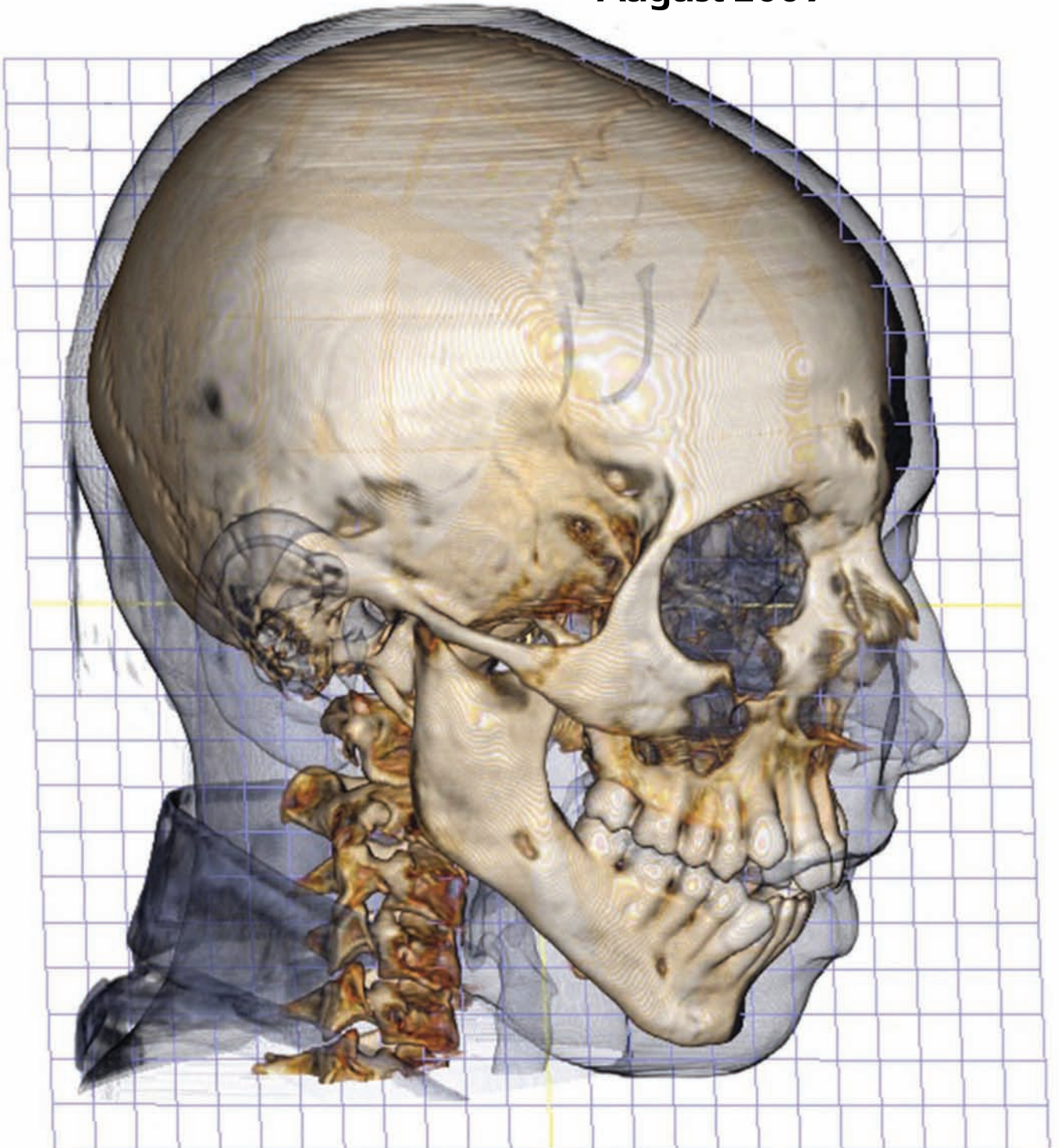


jco

www.jco-online.com

**JOURNAL OF
CLINICAL
ORTHODONTICS**

August 2009



THE CUTTING EDGE

(Editor's Note: This quarterly column is compiled by JCO Technology Editor Ronald Redmond. To help keep our readers on The Cutting Edge, Dr. Redmond will spotlight a particular area of orthodontic technology every three months. Your suggestions for future subjects or authors are welcome.)

Lewis Carroll used Alice in Wonderland to describe a paradigm shift. While it may have been one that Alice could not immediately comprehend when she fell into the rabbit hole, she did recognize that things were not as they were and that she couldn't use her previous mind-sets to interpret the current data. As I perused Dr. Doug Chenin's article on dynamic cone-beam computed tomography (CBCT), it occurred to me that we orthodontists have reached that same state of affairs.

In this month's column, Dr. Chenin presents the full range of capabilities of the Anatomage InVivoDental software. This program, created by Dr. Jack Choi (playing the part of the White Rabbit), magically transforms CBCT into usable diagnostic information. One cone-beam scan produces a panorex, lateral and frontal headfilms (and everything in between), study models, a TMJ series, airway analysis, superimpositions for growth assessment and surgical prediction, soft-tissue analysis, and anatomical articulation of the dentition. In addition, Anatomage is developing the capability to generate physical appliances from the same cone-beam scan (did someone say "no more polyvinyl siloxane impressions"?).

Last November, in a presentation to the Canadian Association of Orthodontists, I stated

that "one cone-beam scan would provide all the diagnostic materials an orthodontist would need and the study models to produce Invisalign aligners and Insignia and SureSmile appliances". My comments created a noticeable buzz in the audience, but now that presentation seems like it was made years ago. Considering the rapid pace of advancement in CBCT and the strides made in designing interpretive software since then, it's no wonder I feel like Alice, tumbling down the rabbit hole.

W. RONALD REDMOND, DDS, MS

Dynamic Cone-Beam Computed Tomography in Orthodontic Treatment

The value of cone-beam computed tomography (CBCT) scans in orthodontic diagnosis has been well established. A single CBCT scan allows reconstruction of the traditional radiographs used for diagnosis and treatment planning and provides views that were previously unavailable.¹⁻⁹ Two important tools needed to complete the diagnostic and treatment-planning package are study models



Dr. Redmond



Dr. D.L. Chenin



Dr. D.A. Chenin



Dr. S.T. Chenin



Dr. Choi

and photographs. These missing pieces are now provided by InVivoDental* three-dimensional imaging software and the AnatoModel* system, which allow the creation of digital study models, integration of digital photographs, and production of virtual treatment setups and simulations.⁹

The AnatoModel

The AnatoModel is a 3D digital study model created directly from the CBCT scan data. Eliminating the need for impressions avoids patient discomfort and saves the orthodontist valuable chairtime, staff time, and materials. The AnatoModel is of higher diagnostic value than other digital models because it includes not only the tooth crowns, but also roots, impactions, developing teeth, and alveolar bone⁹ (Fig. 1). Essentially, it is a model of the patient's complete dental anatomy.

*Anatamage, Inc., 111 N. Market St., Suite 800, San Jose, CA 95113; www.anatamage.com. InVivoDental is a trademark.

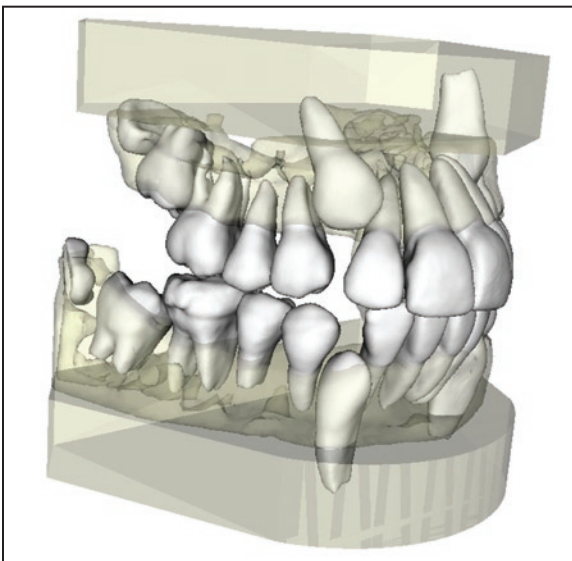


Fig. 1 AnatoModel* with transparent alveolar bone, allowing visualization of roots and developing teeth attached to plaster-like virtual bases. (All images generated with InVivoDental 3D software.)

This 3D virtual modeling involves segmenting the scan data into individual anatomical structures, allowing the data to be manipulated in ways that are not possible with raw Digital Imaging and Communications in Medicine (DICOM) data. For example, each dental arch can be separated from the rest of the scan data and viewed from an occlusal perspective, even if the scan was taken with the patient in full occlusion (Fig. 2A). Moreover, alveolar bone can be virtually removed to

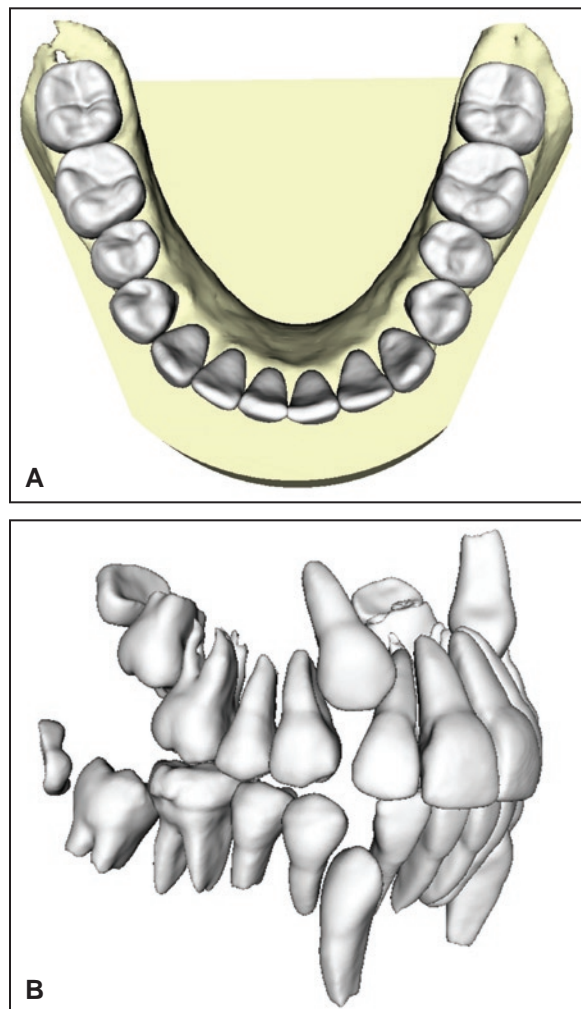


Fig. 2 AnatoModels created from scans with teeth in full occlusion. A. Isolation of mandibular arch for occlusal view. B. Virtual removal of alveolar bone to isolate teeth.

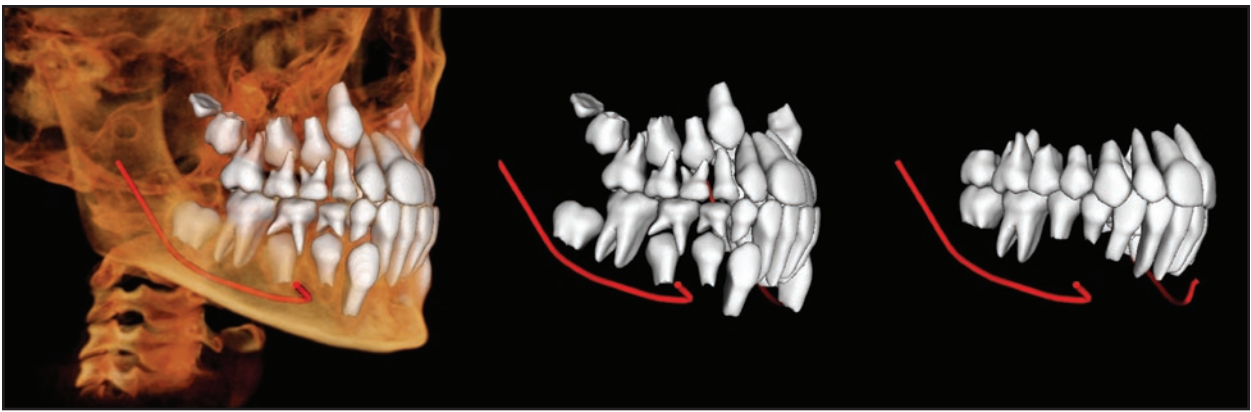


Fig. 3 AnatoModel and dynamic cone-beam computed tomography (CBCT) orthodontic treatment simulation involving patient's complete dental anatomy.

visualize the teeth independently (Fig. 2B). This is especially useful in mixed-dentition patients and in cases involving impactions. Because the modeled teeth can be moved individually to the desired end-point locations and orientations, the segmentation process facilitates virtual setups and dynamic treatment simulation. The skeletal anatomy can also be segmented and manipulated to create 3D virtual treatment plans for orthognathic surgery.

The resulting orthodontic and orthognathic treatment simulation, involving the patient's entire dental anatomy (Fig. 3), provides the foundation for the next generation of CBCT technology: "dynamic CBCT". As the technology develops, the CBCT-based orthodontic treatment plan will be integrated into the design of such therapeutic devices as indirect-bonding appliances and orthognathic surgical guides.

Resolving the Problem of Noise Artifacts

Metallic restorations create noise artifacts in the data collected from a CBCT scan. This can hinder the creation of accurate digital models, especially in patients with multiple restorations.^{9,10} Typically, the crowns are affected to a greater degree than the roots.¹⁰ Although impressions are not needed to create AnatoModels, they can be used to avoid noise artifacts by integrating information from a study cast into the CBCT scan data. Thus, the crown anatomy is derived from impressions, and the root and bone anatomy from the CBCT scan.

Mapping Digital Photographs onto 3D CBCT Scans

Merging DICOM data with a standard digital

frontal photograph of the patient creates a 3D facial photograph without the need for a complex and expensive 3D facial camera system⁹ (Fig. 4). The two data sets are combined by mapping a photograph taken with any digital camera over the external soft-tissue morphology captured by the CBCT scan, based on common reference points.

The digital models and the photograph

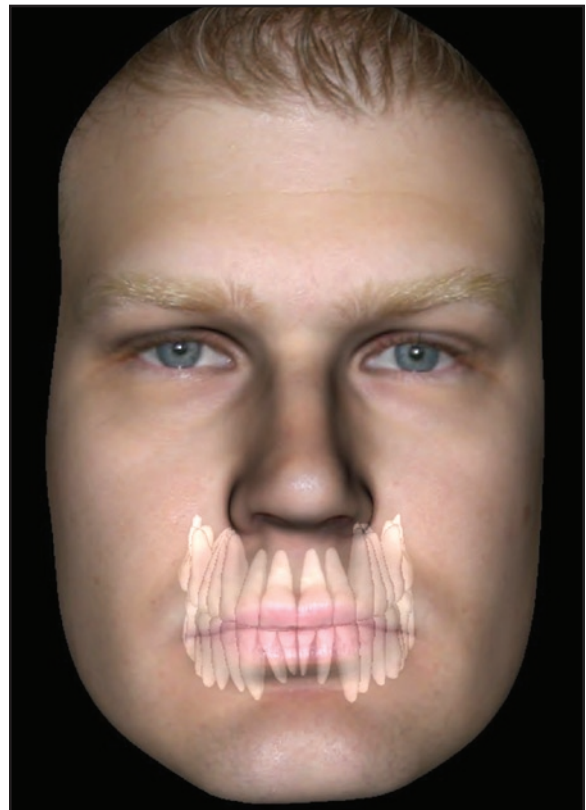


Fig. 4 Three-dimensional photograph created from two-dimensional digital photograph mapped to CBCT scan, showing modeled teeth.

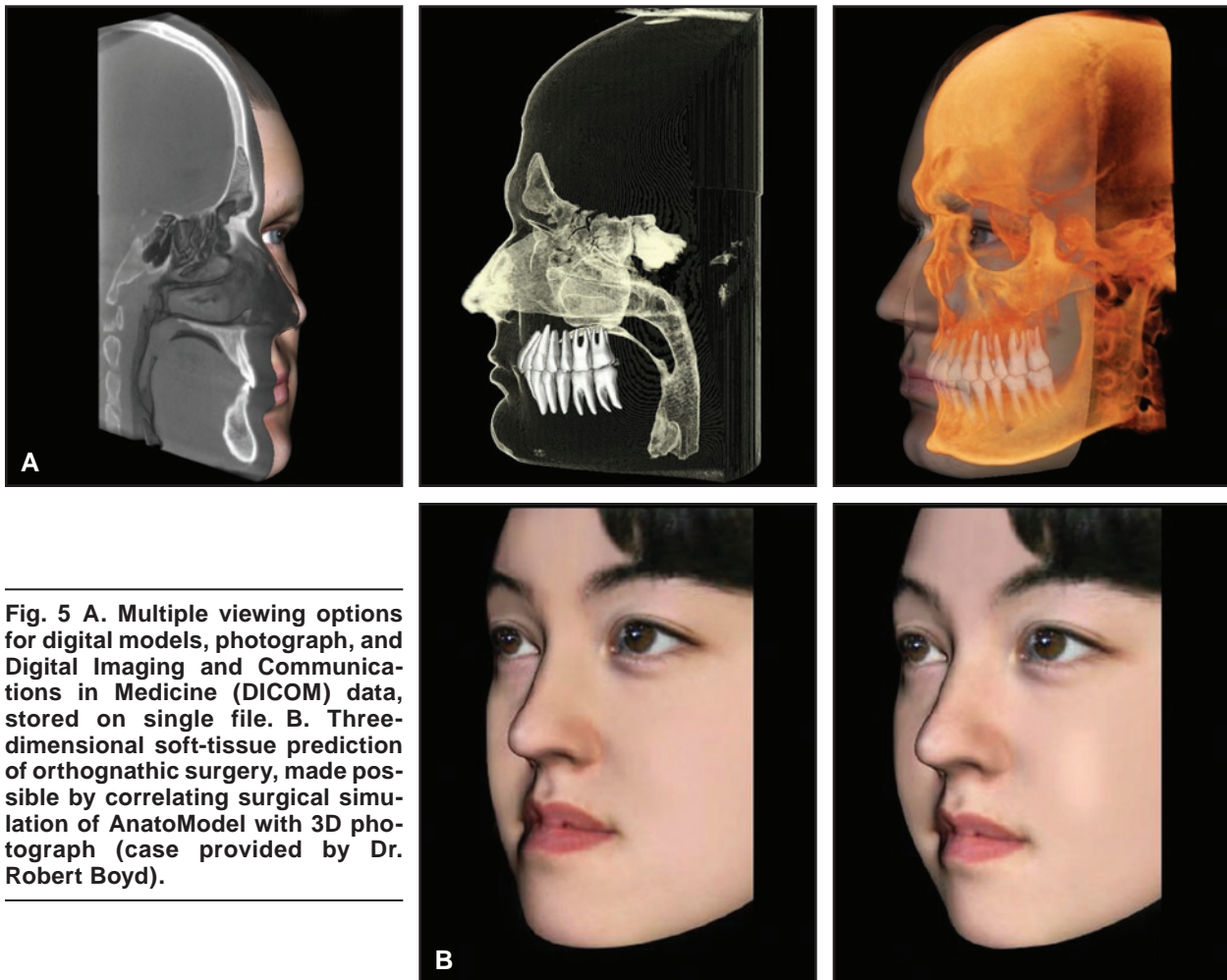


Fig. 5 A. Multiple viewing options for digital models, photograph, and Digital Imaging and Communications in Medicine (DICOM) data, stored on single file. **B.** Three-dimensional soft-tissue prediction of orthognathic surgery, made possible by correlating surgical simulation of AnatoModel with 3D photograph (case provided by Dr. Robert Boyd).

appear in their correct anatomical positions in relation to each other and are stored in a single data file (Fig. 5A). This allows assessment and demonstration of how skeletal relationships and tooth positions affect a patient's facial profile and esthetic appearance. Dynamic orthodontic and surgical simulations with the hard tissues of the AnatoModels can also be correlated with the external soft tissues and 3D photograph, providing a 3D soft-tissue prediction that demonstrates how a patient's esthetics can be enhanced with orthodontic treatment and orthognathic surgery (Fig. 5B).

3D Superimposition Technology

Superimpositions of cephalometric radiographs have long been used to assess orthodontic treatment outcomes and track patient growth.^{11,12}

InVivoDental 3D imaging software allows two CBCT scans to be opened at the same time and superimposed by registering common stable landmarks. The result is a 3D volume rendering of both scans, fused with different colorizations to highlight the differences between them. Cross-sectional visualizations of the superimposed data sets allow assessment of the internal structures.

This technique can be used to assess changes occurring between any two scans, whether from orthodontic treatment (Fig. 6A), orthognathic surgery (Fig. 6B), or growth and development. It can be used to assess the TMJ and airway by superimposing scans with the patient in different jaw positions (Fig. 6C). Changes in the airway produced by dental sleep-apnea devices and airway-related surgeries can also be assessed^{13,14} (Fig. 6D).

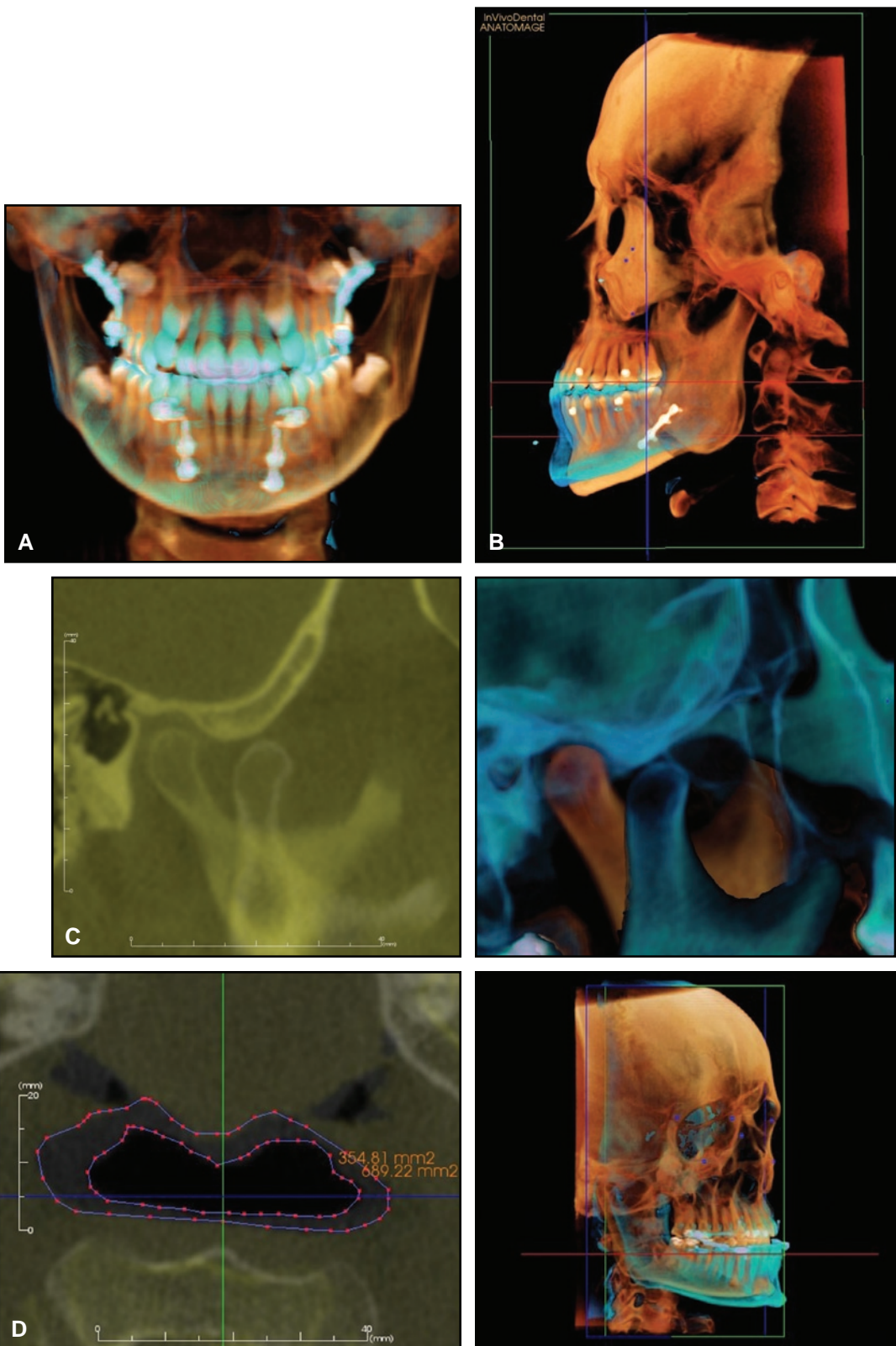


Fig. 6 A. Superimposition of pre- and post-treatment scans, showing canine eruption and widening of maxillary arch. B. Superimposition of pre- and postsurgical scans (case provided by Dr. Robert Boyd). C. Superimposition of TMJ scans in open and closed positions. D. Superimposition of CBCT scans with and without mandibular advancement device for sleep apnea, showing change in airway (case provided by Drs. John McCrillis and Allan Farman).

Future Developments in CBCT Technology

Three-dimensional CBCT-based hard- and soft-tissue simulations, photographic integration, and superimpositions have ushered in a new era of dynamic CBCT imaging. Future developments in this field offer the promise of even greater benefits for orthodontic diagnosis and treatment.

AnatoModels can serve as a starting point for creating a 3D virtual articulator based on the patient's actual skeletal and dental anatomy (Fig. 7). They can also be correlated with jaw-tracking systems to illustrate patient-specific jaw movements.⁹ The most advanced virtual setups would take into consideration both the occlusion and the TMJ function. Three-dimensional volume renderings make it possible for all this information to be stored in a single data file, which will allow simultaneous 3D virtual treatment planning and simulation involving dental setups, skeletal surgeries, 3D photographs, jaw tracking, and articulation. Ultimately, this virtual treatment plan could be connected to indirect therapeutic devices, thus transforming it into clinical reality.

DOUGLAS L. CHENIN, DDS
 Director of Clinical Affairs
 Anatomage, Inc.
 111 N. Market St., Suite 800
 San Jose, CA 95113
 drdougchenin@anatomage.com

DAVID A. CHENIN, DDS, MSD
 Clinical Advisor, Anatomage, Inc.
 Henderson, NV

STEPHEN T. CHENIN, DDS
 Henderson, NV

JACK CHOI, PHD
 Chief Executive Officer
 Anatomage, Inc.
 San Jose, CA

REFERENCES

1. Mah, J. and Hatcher, D.: Three-dimensional craniofacial imaging, *Am. J. Orthod.* 126:308-309, 2004.
2. Kau, C.H.; Richmond, S.; Palomo, J.M.; and Hans, M.G.:

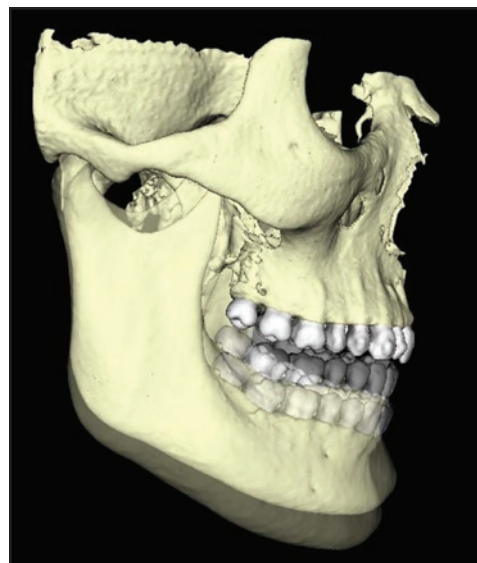

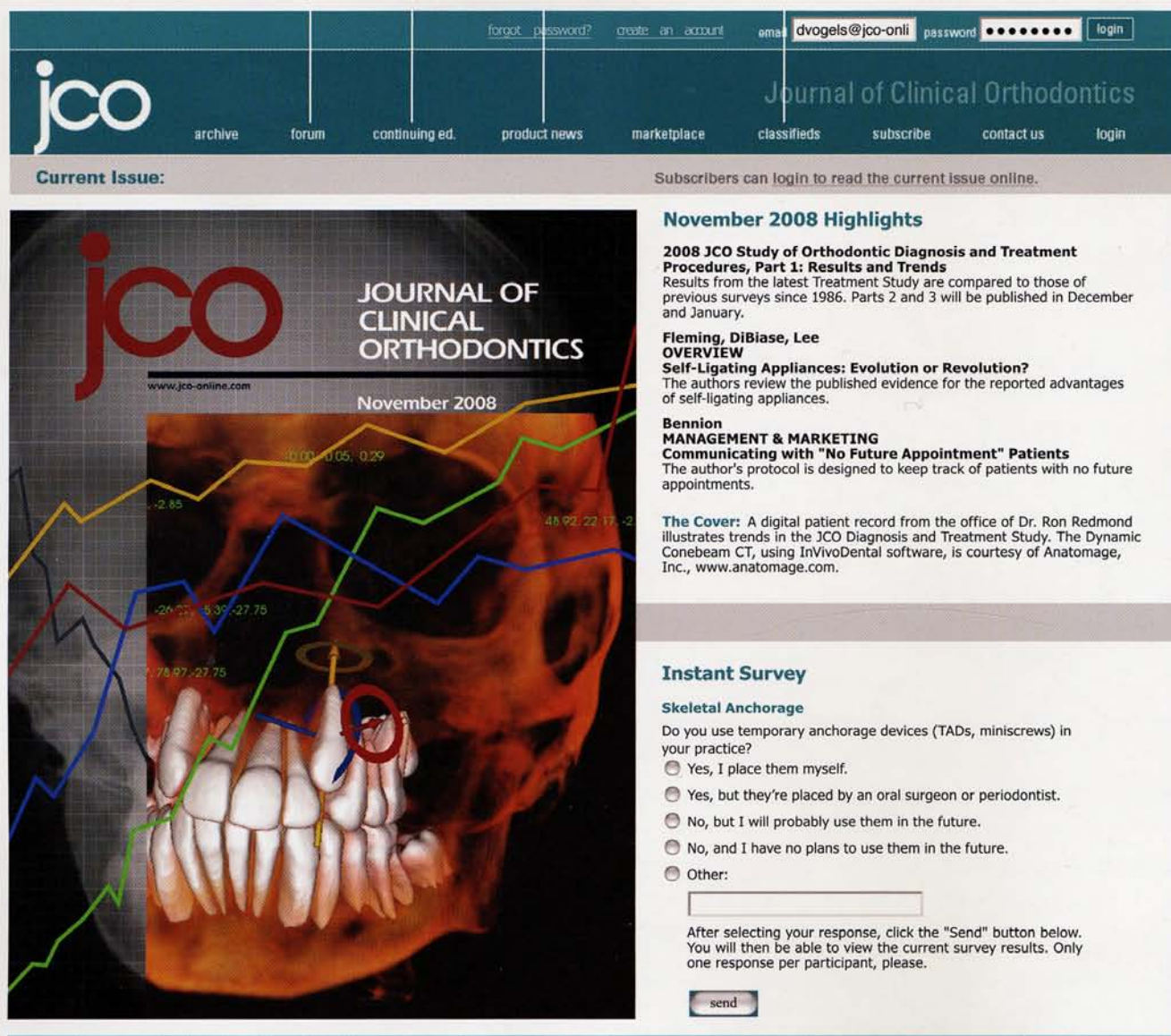
Fig. 7 Upper and lower jaw modeling for 3D digital articulation.

- Three-dimensional cone beam computerized tomography in orthodontics, *J. Orthod.* 32:282-293, 2005.
3. Maverna, R. and Gracco, A.: Different diagnostic tools for the localization of impacted maxillary canines: Clinical considerations, *Prog. Orthod.* 8:28-44, 2007.
4. Howerton, W.B. Jr. and Mora, M.A.: Use of conebeam computed tomography in dentistry, *Gen. Dent.* 55:54-57, 2007.
5. Hutchinson, S.Y.: Cone beam computed tomography panoramic images vs. traditional panoramic radiographs, *Am. J. Orthod.* 128:550, 2005.
6. Peck, J.L.; Sameshima, G.T.; Miller, A.; Worth, P.; and Hatcher, D.C.: Mesiodistal root angulation using panoramic and cone beam CT, *Angle Orthod.* 77:206-213, 2007.
7. Liu, D.G.; Zhang, W.L.; Zhang, Z.Y.; Wu, Y.T.; and Ma, X.C.: Three-dimensional evaluations of supernumerary teeth using cone-beam computed tomography for 487 cases, *Oral Surg. Oral Med. Oral Pathol. Oral Radiol. Endod.* 103:403-411, 2007.
8. Scarfe, W.C.; Farman, A.G.; and Sukovic, P.: Clinical applications of cone-beam computed tomography in dental practice, *J. Can. Dent. Assoc.* 72:75-80, 2006.
9. Mah, J.: The evolution of digital study models, *J. Clin. Orthod.* 41:557-561, 2007.
10. Holberg, C.; Steinhäuser, S.; Geis, P.; and Rudzki-Janson, I.: Cone-beam computed tomography in orthodontics: Benefits and limitations, *J. Orofac. Orthop.* 66:434-444, 2005.
11. Tsau, J.N.; Carlson, S.K.; Boyd, R.L.; and Baumrind, S.: Superimposition of serial cephalometric images directly on a computer monitor, *Penn. Dent. J.* 102:11, 2002.
12. Goel, S.; Bansal, M.; and Kalra, A.: A preliminary assessment of cephalometric orthodontic superimposition, *Eur. J. Orthod.* 26:217-222, 2004.
13. McCrillis, J.; Farman, A.; Scarfe, W.; Haskell, J.; Brammer, M.; and Chenin, D.: Segmentation of the airway using CBCT in obstructive sleep apnea with and without placement of mandibular advancement device, *Int. J. CARS* 3(Suppl. 1):S208-S210, 2008.
14. McCrillis, J.M.; Haskell, J.; Haskell, B.S.; Brammer, M.; Chenin, D.; Scarfe, W.C.; and Farman, A.G.: Obstructive sleep apnea and the use of cone beam computed tomography in airway imaging: A review, *Semin. Orthod.* 15:63-69, 2009.

Knowledge is e-ssential.

Explore the Cutting Edge of orthodontics with the latest information on treatment techniques and management innovations.

www.jco-online.com



The screenshot shows the JCO website interface. At the top, there is a navigation bar with the JCO logo and links for archive, forum, continuing ed., product news, marketplace, classifieds, subscribe, contact us, and login. A user login area is visible with the email 'dvogels@jco-onli' and a password field. Below the navigation bar, the 'Current Issue:' section features the November 2008 cover of the Journal of Clinical Orthodontics. The cover displays a 3D model of a human skull with a dynamic conebeam CT scan overlaid, showing various data points and trends. To the right of the cover, the 'November 2008 Highlights' section lists several articles, including '2008 JCO Study of Orthodontic Diagnosis and Treatment Procedures, Part 1: Results and Trends', 'Fleming, DiBiase, Lee OVERVIEW Self-Ligating Appliances: Evolution or Revolution?', and 'Bennion MANAGEMENT & MARKETING Communicating with "No Future Appointment" Patients'. Below the highlights, there is an 'Instant Survey' section titled 'Skeletal Anchorage' with a list of radio button options and a 'send' button.

forget password? create an account email password login

jco archive forum continuing ed. product news marketplace classifieds subscribe contact us login

Journal of Clinical Orthodontics

Current Issue: Subscribers can login to read the current issue online.

November 2008 Highlights

2008 JCO Study of Orthodontic Diagnosis and Treatment Procedures, Part 1: Results and Trends
Results from the latest Treatment Study are compared to those of previous surveys since 1986. Parts 2 and 3 will be published in December and January.

Fleming, DiBiase, Lee
OVERVIEW
Self-Ligating Appliances: Evolution or Revolution?
The authors review the published evidence for the reported advantages of self-ligating appliances.

Bennion
MANAGEMENT & MARKETING
Communicating with "No Future Appointment" Patients
The author's protocol is designed to keep track of patients with no future appointments.

The Cover: A digital patient record from the office of Dr. Ron Redmond illustrates trends in the JCO Diagnosis and Treatment Study. The Dynamic Conebeam CT, using InVivoDental software, is courtesy of Anatomage, Inc., www.anatomage.com.

Instant Survey

Skeletal Anchorage

Do you use temporary anchorage devices (TADs, miniscrews) in your practice?

Yes, I place them myself.

Yes, but they're placed by an oral surgeon or periodontist.

No, but I will probably use them in the future.

No, and I have no plans to use them in the future.

Other:

After selecting your response, click the "Send" button below. You will then be able to view the current survey results. Only one response per participant, please.

Searchable Online Archive

Subscribers to the print journal have access to all articles online. The Online Archive includes virtually every JCO article from 1967 to the current issue. Online-only subscriptions are available, including access to the complete Online Archive.

Contact us about institutional and student rates.

Continuing Education

Users can earn C.E. credits online with payment by VISA or MasterCard. Certificates are immediately available for downloading and printing.

Product News

New products and services featured in each print issue are available online in a searchable data base.

Online Forum

Users can join in threaded discussions of clinical and management topics of interest to orthodontists. Replies are posted instantly.

Online Classifieds

Classified ads are posted within days of receipt. E-mail and website links are posted at no extra charge.